



Clinic Information

Clinic

AIS Demonstration Center
17620 MT Hermann St
Fountain Valley, CA, 92708

Referring Veterinarian

Demo Donna

(877) 727-6800

Patient Information

Name

ThoraxAbdomenandLimbs

Patient ID

30851

Owner

Diane Wilson

Species

Canine

Breed

Labrador Retriever

Sex

N

Date of Birth

19 Sep 2016

Study Information

Study Date

12/08/2023

Modality

[\[DX\]_9](#)

Pertinent Case Information

No additional details entered.

Clinical Observations

Healthy patient / No clinical signs / Normal physical exam

AI Findings

Gastrointestinal

Gastric Foreign Material (debris)

Study Notes

Assessment

9 radiographs (abdomen, limbs and thorax) were evaluated by RapidRead.

The material in the stomach likely represents dietary indiscretion. Given the lack of reported GI signs, this is likely an incidental finding. Should GI signs appear, additional radiographs are recommended.

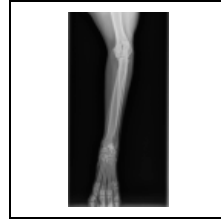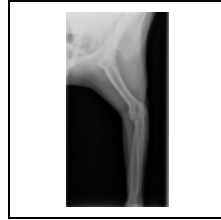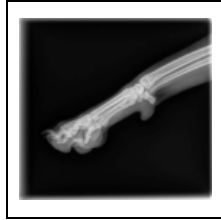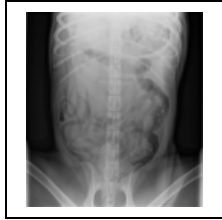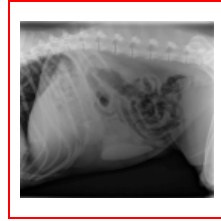
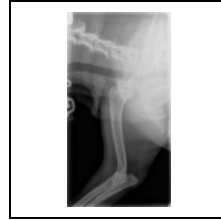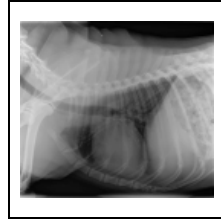
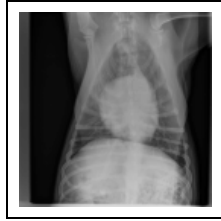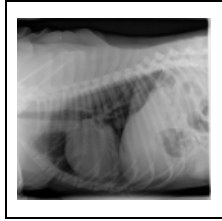There are no AI evaluated findings in the included limbs or thorax images. Please click the link at the bottom of this report for a full list of evaluated findings. If there is clinical concern for a finding not evaluated by RapidRead, please submit the case for radiologist review

VHS

VHS: 10.6

Normal Range: 10.3 - 10.5

Images Evaluated



Disclaimer: This study has been reviewed by AI only. The results should not be used alone, they must be taken in context with all other clinical information.

Requesting a Radiologist Review: You may request a review of this case by an AIS radiologist by [clicking here](#). Please note the RapidRead fee will be credited, and you will be charged your standard AIS fee for the radiology review. The turnaround time is approximately 24-48 hours.

If your patient is critical, you may request a STAT AIS radiologist read by [clicking here](#). Please note the RapidRead fee will be credited, and you will be charged your standard AIS fee (including the STAT fee) for the radiology review. The turnaround time is approximately 2 hours.

If RapidRead identifies any life-threatening finding, the consult will automatically be sent for a STAT radiology review at no additional cost to the clinic. The turnaround time is approximately 2 hours.

Survey:

Please give us feedback on this report, take the short survey by clicking [HERE](#).

List of Conditions Tested

Cardiovascular

- Aortic Arch Enlargement
- Cardiomegaly
- Heart Base Mass Effect
- Left Atrial Enlargement
- Left Ventricular Enlargement
- Main Pulmonary Artery Enlargement
- Microcardia
- Right Atrial Enlargement
- Right Ventricular Enlargement
- Vertebral Heart Score

Gastrointestinal

- Esophageal Dilation
- Gastric Dilatation Volvulus
- Gastric Distention
- **Gastric Foreign Material (debris)**
- Small Intestinal Obstruction

Hepatobiliary

- Hepatic Mineralization
- Hepatomegaly

Mediastinum

- Mediastinal Widening/Opacity
- Sternal Lymph Node Enlargement

Other Abdominal

- Caudal Abdominal Mass
- Cranial Abdominal Mass
- Decreased serosal detail
- Mid Abdominal Mass
- Splenomegaly

Pleural Space

- Pleural Mass Effect
- Pneumothorax
- Sign(s) of Pleural Effusion
- Thin Pleural Fissure Line(s)

Pulmonary Structures

- Bronchial Pattern
- Tracheal Narrowing or Opacity
- Unstructured Interstitial Pattern
- Alveolar Pattern
- Pulmonary Interstitial – Nodule(s)
- Pulmonary Vascular

Skeletal

- Aggressive Bone Lesion
- Degenerative Joint Disease
- Limb Fracture
- Sign(s) of IVDD
- Spondylosis

- *Stifle Effusion*

Soft Tissue

- *Fat Opacity Mass (e.g. lipoma)*
- *Subcutaneous Mass*
- *Subcutaneous Nodule*

Urogenital

- *Misshapen Kidney(s)*
- *Prostatic Enlargement*
- *Renal Mineralization*
- *Small Kidney(s)*
- *Urinary Bladder Calculus/Calculi*
- *Uterine Enlargement*