QUARTERLY
LEARNING SERIES

A Publication of Antech Imaging Services
Fall 2021 / Volume 5, No. 4

The Coughing Dog - Is it Left Heart Failure?

by Nancy E. Love DVM, DACVR

As a teleradiologist at AIS, I see cases from across the US and Canada. I typically see at least one case a day (generally more) where the clinical question is "The patient is coughing, is it in heart failure?" This article will provide information to help you, the clinician make that decision. The discussion will focus on radiographic findings in the dog.

1. Quality Control

We will start with the quality of the radiographs. This is generally not considered the "fun" part of reviewing images; however, the quality of the radiographs has a strong positive (or negative) impact on interpretation of cardiac disease.

Number of Images/Views Made

Cardiac studies should have a minimum of 2 images, a lateral (LAT) view and VD view. Although a right LAT and VD view is commonly selected, it is more important that the same orthogonal views are made in your practice. Familiarity with the same views, decreases a variable when interpreting radiographs. Since the original vertebral heart score (VHS) studies were done on right lateral (RLAT) views, a RLAT is recommended if a VHS is requested. A DV view is fine, particularly if the patient is compromised, or this is the common view in your practice. Understand however, that the DV view can sometimes be more difficult to position correctly.

Anatomical Boundaries

Both lateral and VD views should include the entire thorax from the level of the thoracic inlet to the tip of the lungs, and the soft tissues ventral to the sternum to the soft tissues dorsal to the spinous processes. A portion of the soft tissues may not be included if the patient is very obese.

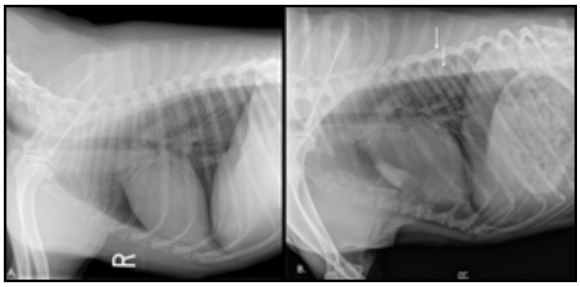

Image 1. A. Correctly positioned RLAT canine thorax. Correct positioning is needed for accurate evaluation of the cardiac silhouette and cardiac measurements. B. Oblique RLAT view of the canine thorax. The ribs are not superimposed (white arrows).

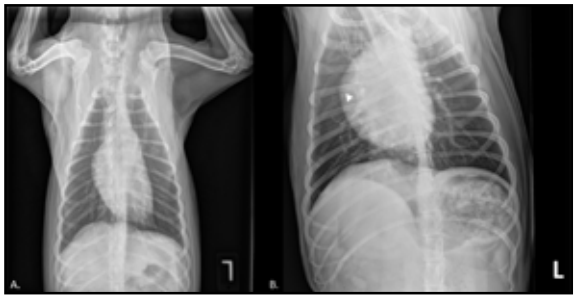

Image 2. A. Correctly positioned VD view canine thorax. B. Oblique VD view of the canine thorax. The sternum is not superimposed (arrowhead), the ribs are not symmetrical (left shorter than right), and the right heart appears artifactually enlarged.

Patient Positioning

Both lateral and VD views should be straight. Mild obliquity can greatly impact the appearance of the cardiac silhouette and make determination of cardiac size and potential chamber enlargement difficult. A straight lateral view is necessary for an accurate measurement of the VHS. The ribs are superimposed (or as close as possible) on the LAT view. The spine and sternum should be superimposed, and the ribs symmetrical on the VD view (Images 1 & 2).

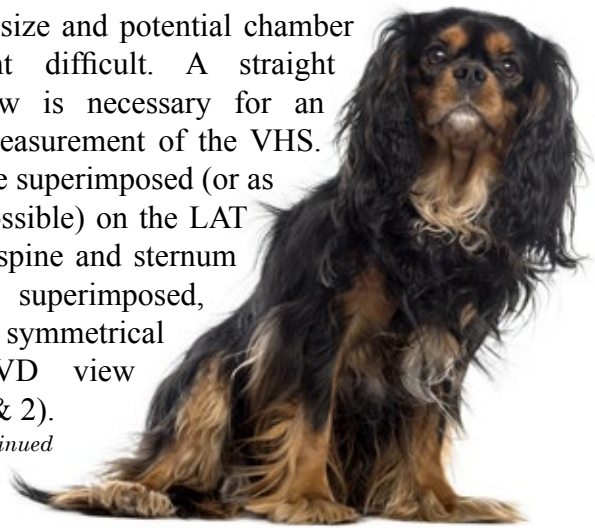

Continued

Phase of Respiration

In an ideal world, films would be made on inspiration, however this is not always possible in a compromised patient. How do you determine inspiration vs expiration? On inspiration the lung field appears larger and there is an increased distance between the cardiac silhouette and diaphragm. When films are made on expiration, the cardiac silhouette may give the artifactual appearance of being larger than it is because it takes up more space in the less expanded thoracic cage.

Radiographic Technique

Digital imaging allows adjustment of less than perfect images, however there are limitations, and the technical staff should strive to attain the best technique possible. Sometimes getting creative with settings (e.g. using the cat abdomen for a small dog thorax) can optimize the technique. A good quality image should allow the viewer to see between the disc spaces on both views and allow visualization of pulmonary markings.

2. Systematic Review of the Radiographs

After quality control has been performed on all the images, it is important to then apply a systematic review of the exam. A systematic review will help the reader evaluate the entire exam and not just "zero in" on expected findings. It is recommended that the reader make a checklist and use that list every time they review radiographic studies to insure a complete evaluation is performed. A systematic review of thoracic radiographs is beyond the scope of this article, however this link https://www.cliniciansbrief.com/article/interpreting-small-animal-thoracic-radiographs to ***Interpreting Small Animal Thoracic Radiographs by Clifford Berry DVM, DACVR*** is an excellent review.

3. Anatomy of the Cardiac Silhouette

Comfort in evaluating the cardiac silhouette on both views will make it easier for the viewer to interpret the exam. Determination of a normal vs abnormal cardiac silhouette begins with knowledge of the radiographic anatomy.

A clockface analogy is commonly used to determine the location of the chambers of the cardiac silhouette. The clockface analogy is helpful in determining specific chamber enlargement (Figure 1).

Figure 1: Anatomy of the Cardiac Silhouette, Lateral and VD View

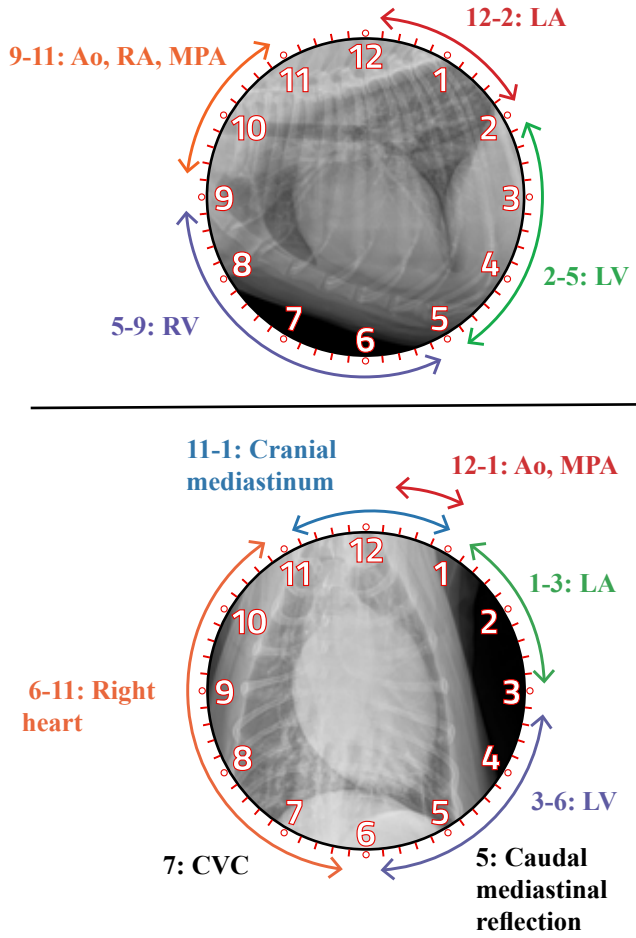

Abbreviations used:
Ao=Aorta, CVC=Caudal Vena Cava, LA=Left Atrium, LV=Left Ventricle, MPA=Main Pulmonary Artery, RA=Right Atrium, RV=Right Ventricle

4. Determination of Cardiac Size

There are many ways to determine cardiac silhouette size on a radiograph, the vertebral heart score is currently popular, but has limitations. The combination of options can help the viewer determine cardiac size with more confidence. It is assumed that evaluation of cardiac size is performed on well positioned images because mild obliquity can greatly impact the appearance of the cardiac silhouette.

Empirical Evaluation on the LAT view

Draw a line from the carina to the apex of the cardiac silhouette. 2/3 of the cardiac silhouette should be cranial to the carina and 1/3 should be caudal to the carina.

Empirical Evaluation on the VD view

The cardiac silhouette is 1/2 - 2/3 the width of the chest cavity.

Continued on next page

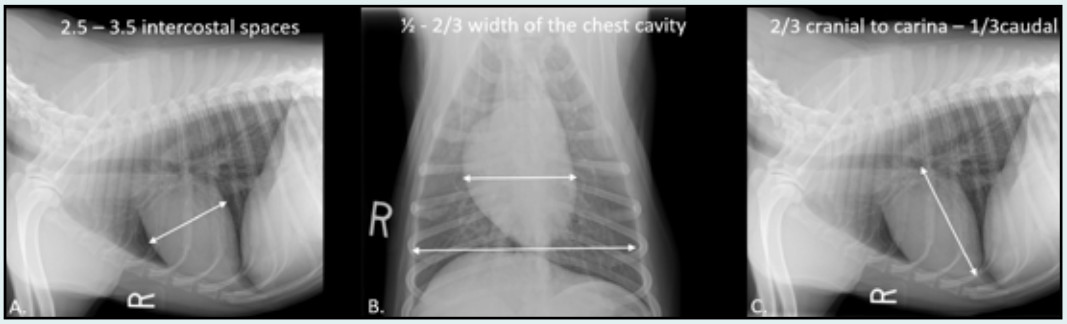

Image 3. A. Normal ICS measurement in the dog. B. and C. Empirical measurement of the canine cardiac silhouette.

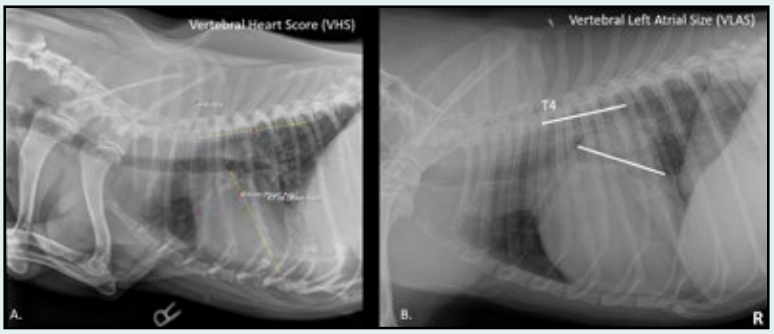

Image 4. A. Normal VHS in a dog with left heart enlargement. B. VLAS measurement in a dog.

Intercostal Spaces (ICS)
Lateral view – 2.5 – 3.5 ICS in the dog (Image 3).
VD/DV view – approximately 2/3 the height of the thorax in the dog and cat.

Vertebral Heart Score (VHS)
The VHS is a measurement tool that has become common to determine the size of the cardiac silhouette. It can be used to monitor progression of cardiac disease and help with treatment planning. The VHS is more reliable if the score is determined by the same viewer between examinations.
The original research was performed on straight right lateral views. There are charts that can be used that consider ranges based on reported patient breed (Table 1, page 6). The VHS is determined by taking a longitudinal measurement from the carina to the apex of the cardiac silhouette, and a short axis measurement from the widest point of the cardiac silhouette parallel to the long axis. Each measurement is then placed at the cranial edge of T4 and the number of vertebrae are counted. The 2 measurements are then added together to determine the VHS. On the AIS viewer, there is a built in VHS measurement tool which simplifies the process.
It must be remembered that a patient with a radiographically abnormal cardiac silhouette can have a normal VHS. Specific chamber enlargement supersedes a normal VHS. So, if there is chamber enlargement, the cardiac silhouette is enlarged even if the VHS is normal.

Vertebral Left Atrial Size (VLAS)
The VLAS is a new measurement tool that is increasing in popularity. The scoring system can be used in patients with mitral valve disease (MVD) and helps determine hemodynamically important MVD in patients where echocardiography may be unavailable. An echocardiogram is recommended to help determine grade B2 (or higher) MVD. Because this is a new measurement tool, additional modifications (such as breed specific ranges) may be forthcoming.
The VLAS is performed on the lateral view by drawing a straight line between the carina and junction of the caudal vena cava and left heart. This measurement is then placed at the cranial margin of T4, and the number of vertebrae identified. A VLAS $\geq$ 2.3-2.5 vertebrae suggest left atrial enlargement with hemodynamically important MVD (Image 4).

5. Radiographic Findings of Left Heart Enlargement
Some radiographic findings associated with left heart enlargement include an increase in the apical basilar

Continued on next page

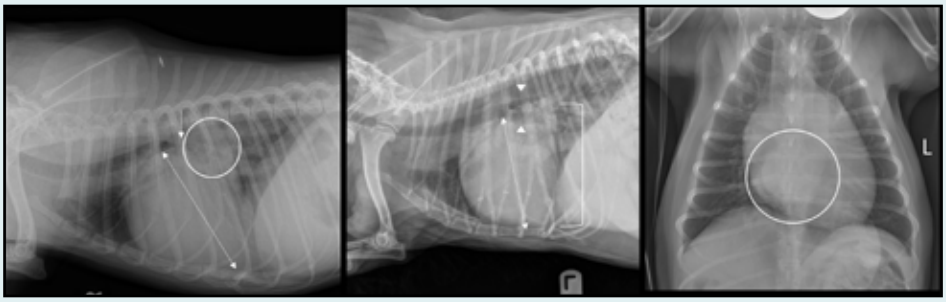

Image 5. Left heart enlargement on all views. There is an increase in the apical basilar length (double arrow), narrowed caudal lobar bronchus (short arrow), separation of caudal lobar bronchi by large left atrium (arrowheads), straight caudal margin (parentheses), enlarged left atrium (circle).

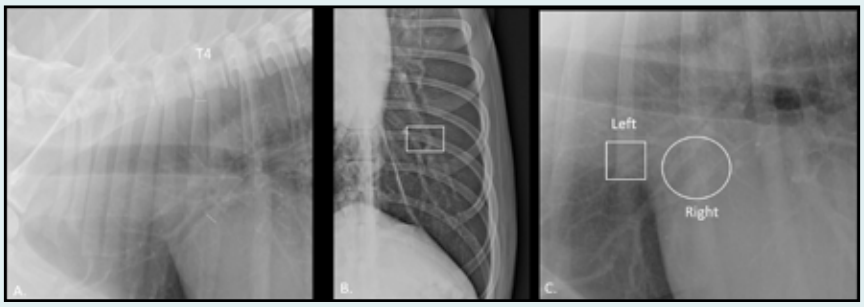

Image 6. A. Normal vein measurement on the LAT view in a dog. B. Normal vessels as they cross the 9th rib on a VD view in the dog (square). C. LLAT view often allows better visualization of cranial lobar vessels. Right vessels (circle) appear larger due to mild magnification on this LLAT view. Note the right artery and vein are similar in size.

length ("tall" heart), a straight caudal margin ("loss of cardiac waist"), elevation of the trachea, a large left atrium, separation and elevation of the caudal lobar bronchi, and compression of a caudal lobar bronchus (Image 5).

6. Pulmonary Vessel Anatomy and Size

There are pulmonary arteries and veins associated with each lung lobe. On the LAT view the artery is dorsal, and the vein ventral, with a bronchus between the two vessels. On the VD view, the artery is lateral, the vein medial, and the bronchus between the two vessels.

Pulmonary vessels can be difficult to see, but every effort should be made to evaluate them. Right and left cranial lobar vessels are often better separated on the LEFT LATERAL view. Caudal lobar vessels are often better visualized on the DV view. Remember to look at cranial <u>and</u> caudal lobar vessels on the LAT and VD/DV views.

Paired pulmonary arteries and veins should be similar in size. Vessel margins should be smooth (not tortuous) and taper distally. In the dog, the diameter of the vessels should not be larger than the proximal aspect of the 4th rib on the LAT view, or larger than where it crosses the 9th rib on the VD/DV view. Vessels that are less than ½ of the rib width are small on either view (Image 6).

If a patient has not been treated with cardiac medication prior to radiographic examination, determination of pulmonary vascular size is used to determine if the patient is in heart failure. Some cardiac medications can make vessels appear normal to small (e.g. diuretics). Enlarged pulmonary arteries and veins or enlarged pulmonary veins can be seen in patients in left heart failure (Image 7).

7. Pulmonary Patterns Associated with Cardiogenic Pulmonary Edema

Unstructured interstitial to alveolar pulmonary pattern

An unstructured interstitial pulmonary pattern is the result of fluid or fibrosis in the interstitial space. Pulmonary vessels, and bronchi are found in the interstitial space. Pulmonary vessels and pulmonary vessel margins are less distinct. Bronchi may be enhanced due to the increased soft tissue opacity surrounding the bronchial walls.

An alveolar pulmonary pattern is due to fluid in the alveoli or collapse of the alveoli (atelectasis). Pulmonary vessels are obscured. The hallmark of an alveolar pattern is the air bronchogram, however an air bronchogram can be obscured if fluid fills the bronchus.

The distribution of the pulmonary pattern is important in determining if left heart failure is present. In patients with cardiogenic pulmonary edema, the pulmonary pattern often originates in the perihilar region and/or right caudal lung lobe and eventually can become patchy or generalized. In patients with

Continued on next page

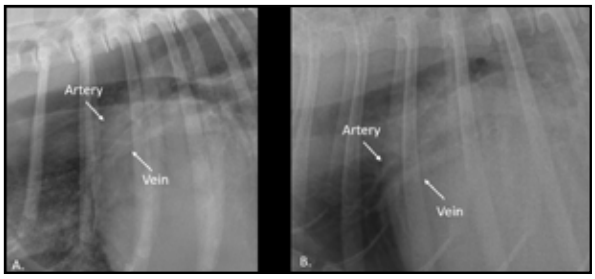

Image 7. A. Enlarged cranial lobar artery and vein in a dog. Note pulmonary edema in the cranial thorax. B. Normal cranial lobar artery and enlarged vein in a dog.

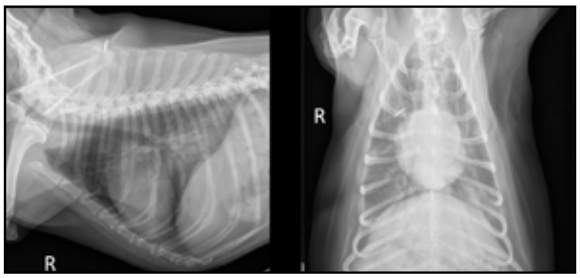

Image 8. RLAT and VD views of a dog with an intense unstructured interstitial pattern in the caudal dorsal lung lobes. This patient has non-cardiogenic pulmonary edema and is not in heart failure.

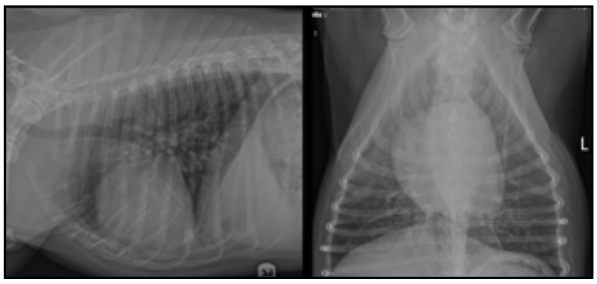

Image 9. Dog with a mild to moderate bronchointerstitial pattern but is not in heart failure. The cardiac silhouette and pulmonary vessels are normal.

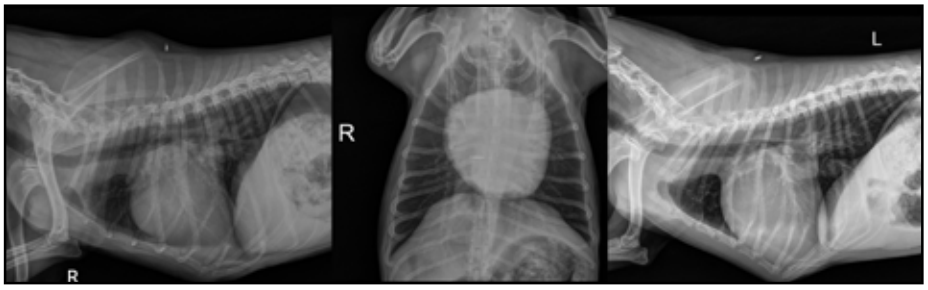

Image 10. 3 view thorax of a dog with left heart enlargement but is not in heart failure. There is an increase in the apical basilar length, the caudal margin of the cardiac silhouette is straight, the left atrium is large, there is venous over circulation. There is also mild narrowing of a caudal lobar bronchus. Pulmonary edema is not identified.

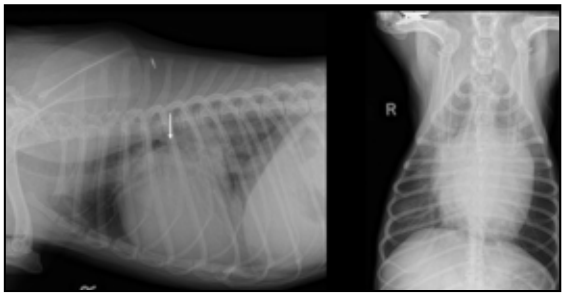

Image 11. RLAT and VD views of a dog in left heart failure. Left heart enlargement (increase in the apical basilar length, left atrial enlargement, venous over circulation (enlarged cranial lobar vein), and patchy unstructured interstitial pattern that is more severe in the right caudal lung lobe). There is also narrowing of a caudal lobar bronchus (arrow).

non-cardiogenic pulmonary edema, the pulmonary pattern is more severe in the caudodorsal lung lobes (Image 8). Remember that you are evaluating the image at a specific moment in time, it may be early, late, or the middle of the disease process, and this may impact the severity and distribution of the pattern.

8. Radiographic Findings of a Coughing Dog without Heart Failure

The absence of cardiomegaly, a murmur, or enlarged pulmonary vasculature is present in patients who have an unstructured interstitial, bronchointerstitial, or alveolar pattern but are not in heart failure (Image 9).

9. Radiographing Findings of a Coughing Dog with Left Heart Enlargement

Left heart enlargement can be present in the absence of enlarged vessels or pulmonary edema. Close evaluation of the vessels, caudal lobar bronchi, and pulmonary pattern is necessary in patients with left heart enlargement and a murmur but no evidence of heart failure. Pulmonary vasculature can be normal or enlarged. The cough may be secondary to bronchial collapse or compression, or chronic respiratory disease (Image 10).

10. Radiographing Findings of a Coughing Dog with Left Heart Enlargement and Pulmonary Edema

There is a fairly classic presentation for left heart failure secondary to mitral valve disease. (Image 11).

- *An increased VHS and/or VLAS*
- *Left atrial and/or ventricular enlargement*
- *Enlarged pulmonary arteries and veins or enlarged pulmonary veins*
- *Unstructured interstitial to alveolar pulmonary pattern (that is not more intense in the caudal dorsal or ventral lung lobes).*

Conclusion

Using the tools presented and a systematic approach to radiographs of coughing dogs, should make it possible for the viewer to determine cardiac disease versus respiratory disease. You've got this!

Table 1. Vertebral Heart Score (VHS) measurements by breed.

DOG BREED	RECUMBENCY	VHS±S.D	NORMAL RANGE	REFERENCE
Various	**Left/Right**	**9.5±0.5**	**8.7-10.7v**	**Buchanan & Bucheler (1995)**
American Pit Bull Terrier	Right	10.9±0.4	10.1-11.7	Lahm et al. (2011)
Beagle	Left	10.2±0.4	9.4-11.0	Kraetschmer et al. (2008)
Beagle	Right	10.5±0.4	9.7-11.3	Kraetschmer et al. (2008)
Boston Terrier	Right	11.7±1.4	8.9-14.5	Jepsen-Grant et al. (2013)
Boxer	Right	11.6±0.8	10.0-13.2	Lamb et al. (2002)
Bulldog	Right	12.7±1.7	9.3-16.1	Jepsen-Grant et al. (2013)
Cavalier King Charles Spaniel	Right	10.6±0.5	9.6-11.6	Lamb et al. (2001)
Dachshund	Right	9.7±0.5	8.7-10.7	Jepsen-Grant et al. (2013)
Doberman	Right	10.0±0.6	8.8-11.2	Lamb et al. (2002)
German shepherd	Right	9.7±0.8	8.1-11.3	Lamb et al. (2001)
Greyhound	Left/Right	10.5±0.1	10.3-10.7	Marin et al. (2007)
Labrador Retriever	Left	10.29±0.04	10.2-10.4	Gugjoo et al. (2013)
Labrador Retriever	Right	10.39±0.05	10.3-10.5	Jepsen-Grant et al. (2013)
Lhasa Apso	Right	9.6±0.8	8.0-11.2	Jepsen-Grant et al. (2013)
Pomeranian	Right	10.5±0.9	8.7-12.3	Jepsen-Grant et al. (2013)
Poodle	Right	10.12±0.51	9.1-11.1	Fonsecapinto & Iwasaki (2004)
Pug	Right	10.7±0.9	8.9-12.5	Jepsen-Grant et al. (2013)
Rottweiler	Left/Right	9.8±0.1	9.6-10.0	Marin et al. (2007)
Shih Tzu	Right	9.5±0.6	8.3-10.7	Jepsen-Grant et al. (2013)
Turkish Shepherd	Left	9.7±0.67	8.4-11.0	Gulanber et al. (2005)
Whippets (Racing pedigree)	Left	11.1±0.4	10.3-11.9	Bavegems et al. (2005)
Whippets (Racing pedigree)	Right	11.4±0.4	10.6-12.2	Bavegems et al. (2005)
Whippets (Show pedigree)	Left	10.5±0.6	9.3-11.7	Bavegems et al. (2005)
Whippets (Show pedigree)	Right	10.8±0.6	9.6-12.0	Bavegems et al. (2005)
Yorkshire Terrier	Right	9.7±0.5	8.7-10.7	Lamb et al. (2001)
Yorkshire Terrier	Right	9.9±0.6	8.7-11.1	Jepsen-Grant et al. (2013)

References
-Boswood A, Häggström J, Gordon SG, et al. (2016) Effect of Pimobendan in dogs with preclinical myxomatous mitral valve disease and cardiomegaly: the EPIC study—a randomized clinical trial. *J Vet Intern Med*. 30: 1765-1779.
-Buchanan JW, Bücheler J (1995) Vertebral scale system to measure heart size in radiographs. *J Am Vet Med Assoc,* 206:194–199.
-Keene, B. W., Atkins, C. E., Bonagura, J.D., et. al. (2019) ACVIM Consensus Guidelines for the Diagnosis and Treatment of Myxomatous Mitral Valve Disease in Dogs. *J Vet Int Med.* 33:1127-1140.
-Schwartz, T., Johnson V.: Manual of Canine and Feline Thoracic Imaging 1st Edition, British Small Animal Veterinary Association, Glouchester, 2008.
-Smith, F.W.K., Tilley, L.P., Oyama, M., Sleeper, M.: Manual of Canine and Feline Cardiology 5th Edition, Elsevier Saunders, St. Louis, Missouri, 2013.